

ABO Sample Cases



The highest commitment to excellence.

Disclaimer

- The following sample questions and answers were composed and vetted by a panel of experts in orthodontics and are intended to provide an example of the types of cases and questions that make up the actual examination.
- During the actual examination, trained examiners, who are all board certified orthodontists, will score responses using rubrics as guides to their decision making.
- Using the rubrics help to create consistency in the decisions the examiners will make as examinees deliver their oral responses. The rubrics are not absolute, as there may be other acceptable answers that are not listed.

Disclaimer Cont.

- The ABO has developed multiple versions of the case-based scenario examination to be used during a test administration cycle. Although the set of cases and questions used on the different versions will not all be the same, all versions follow the same content framework as defined by the practice analysis study.
- Scores will be computed using equating procedures to ensure that all versions are of the same difficulty.
- Review of these sample cases does not guarantee that a candidate will pass the examination.

Sample Case #1

Opening Scenario:

A 10-year, 8-month-old female has been referred by a dentist for an orthodontic evaluation. The mother's chief complaint is that her daughter "doesn't have room for all of her teeth."

Sample Case #1

Question 1

Classification

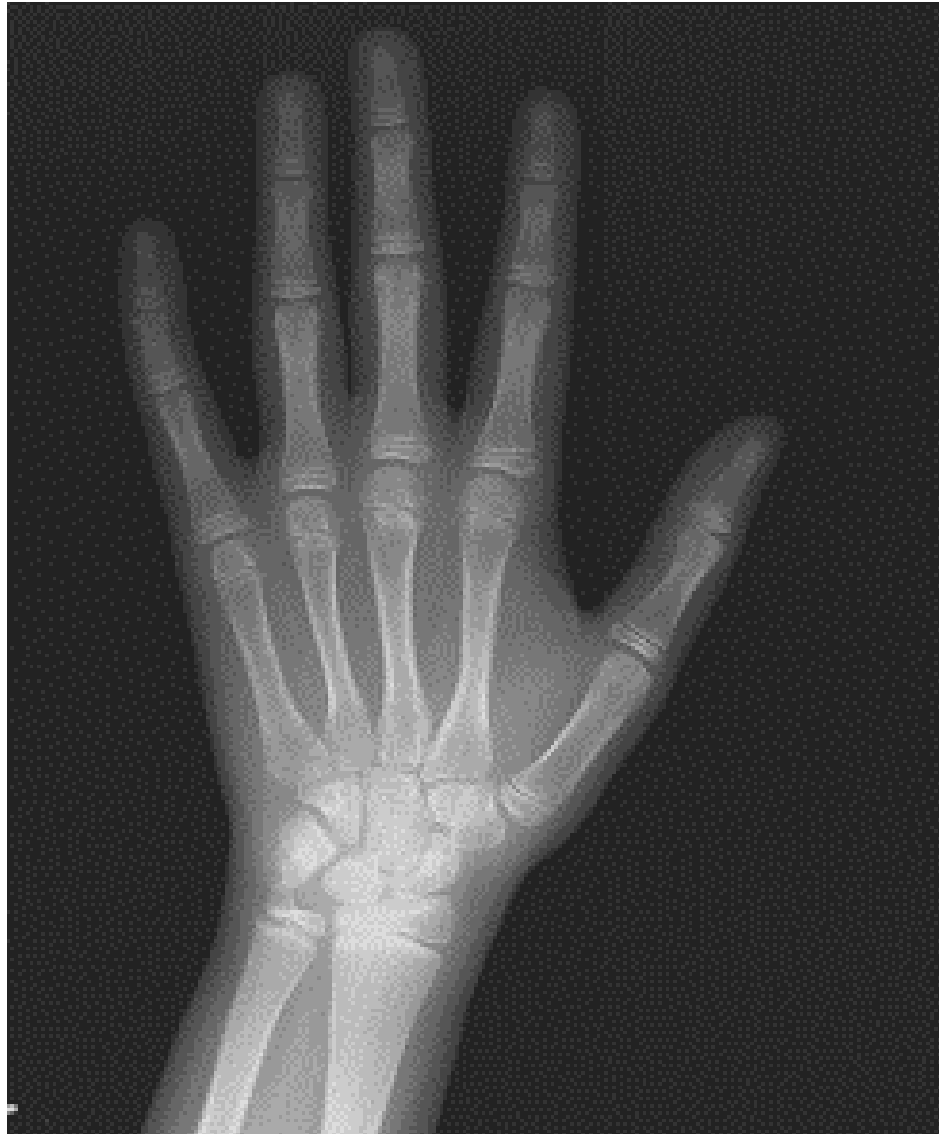Domain 1: Data Gathering and Diagnosis

Prompt

Which skeletal maturation indicators can be used when evaluating the hand-wrist film?

Sample Case #1

Question 1



Sample Case #1

Question 1

A proficient response may include:

- Epiphyseal widening
- Ossification (appearance of adductor sesamoid)
- Epiphyseal capping
- Epiphyseal fusion

Sample Case #1

Question 2

Classification

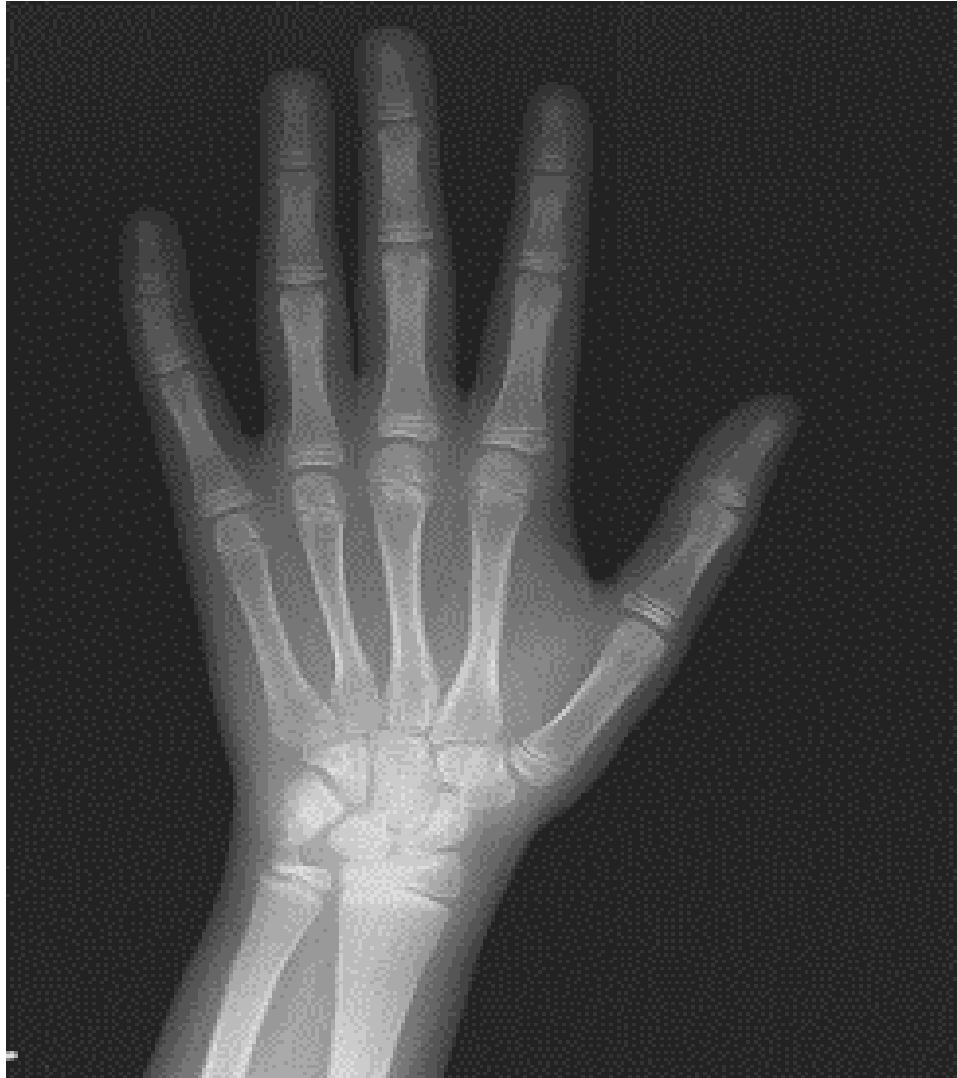Domain 1: Data Gathering and Diagnosis

Prompt

Assess the skeletal maturation of this patient and determine the skeletal maturity from those indicators.

Sample Case #1

Question 2



Sample Case #1

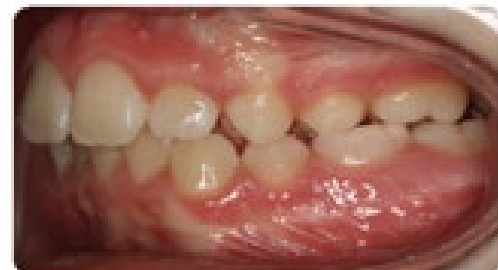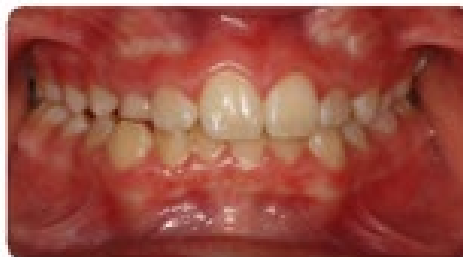
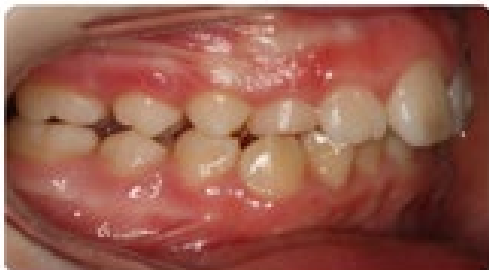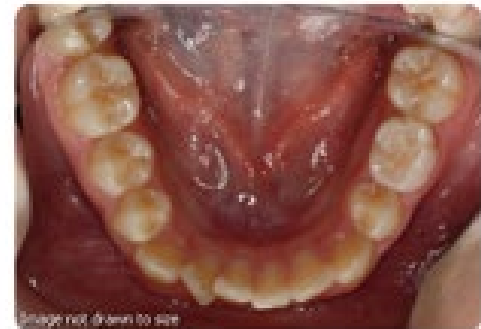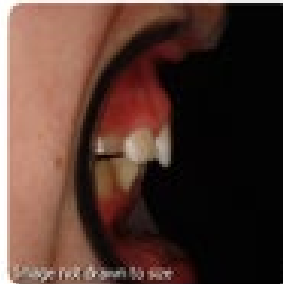


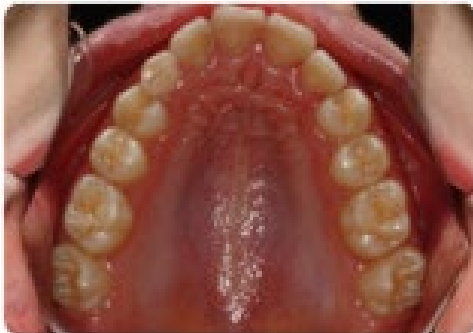Question 2

A proficient response may include:

- Width of epiphysis equal in width to diaphysis
- Lack of presence of the adductor sesamoid
- Lack of epiphyseal capping
- Lack of epiphyseal fusion
- Evaluation of skeletal maturation indicators suggest patient is at level 3-4, approaching peak velocity of growth with significant growth remaining

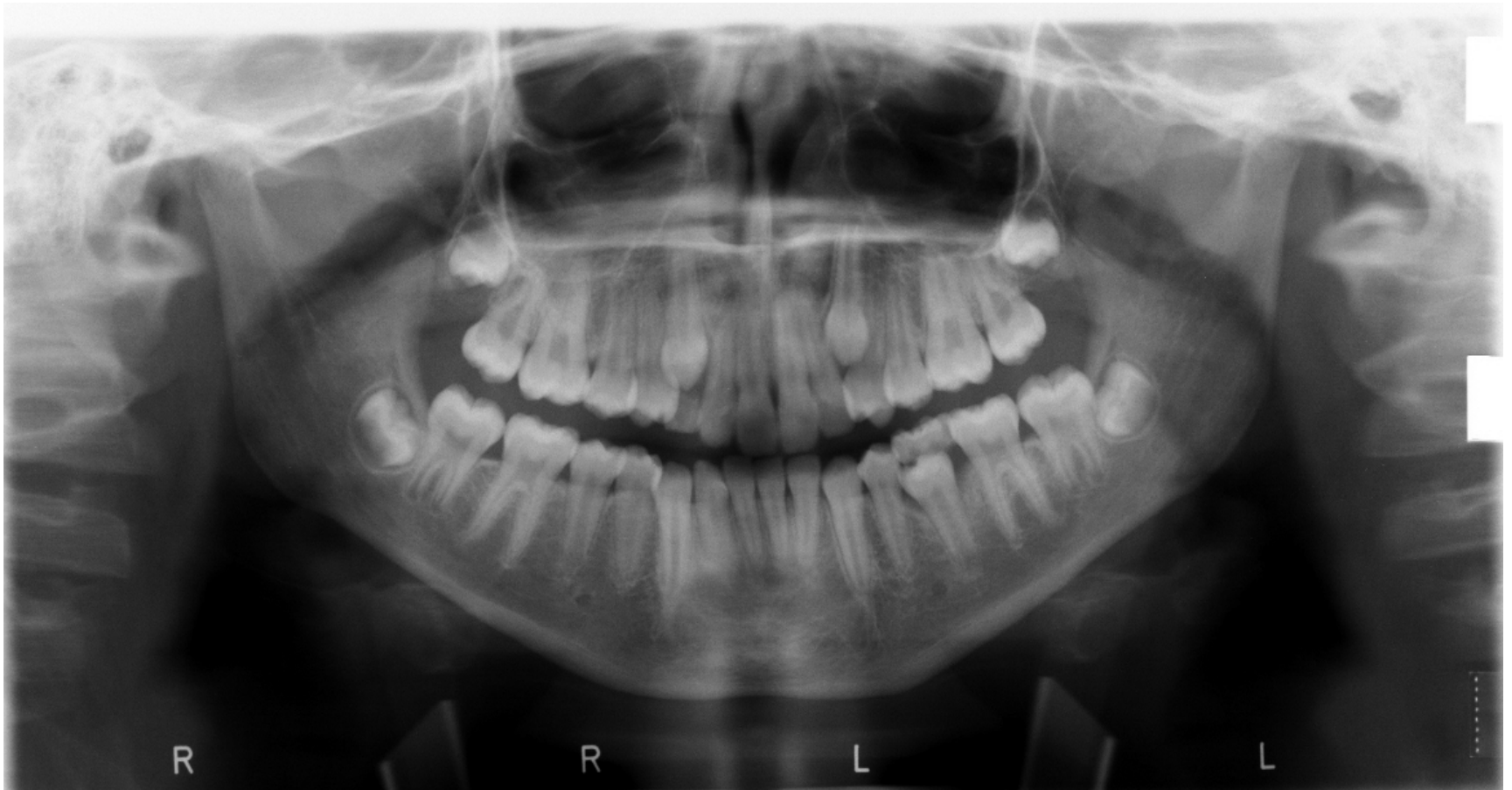
Sample Case #1

Question 3



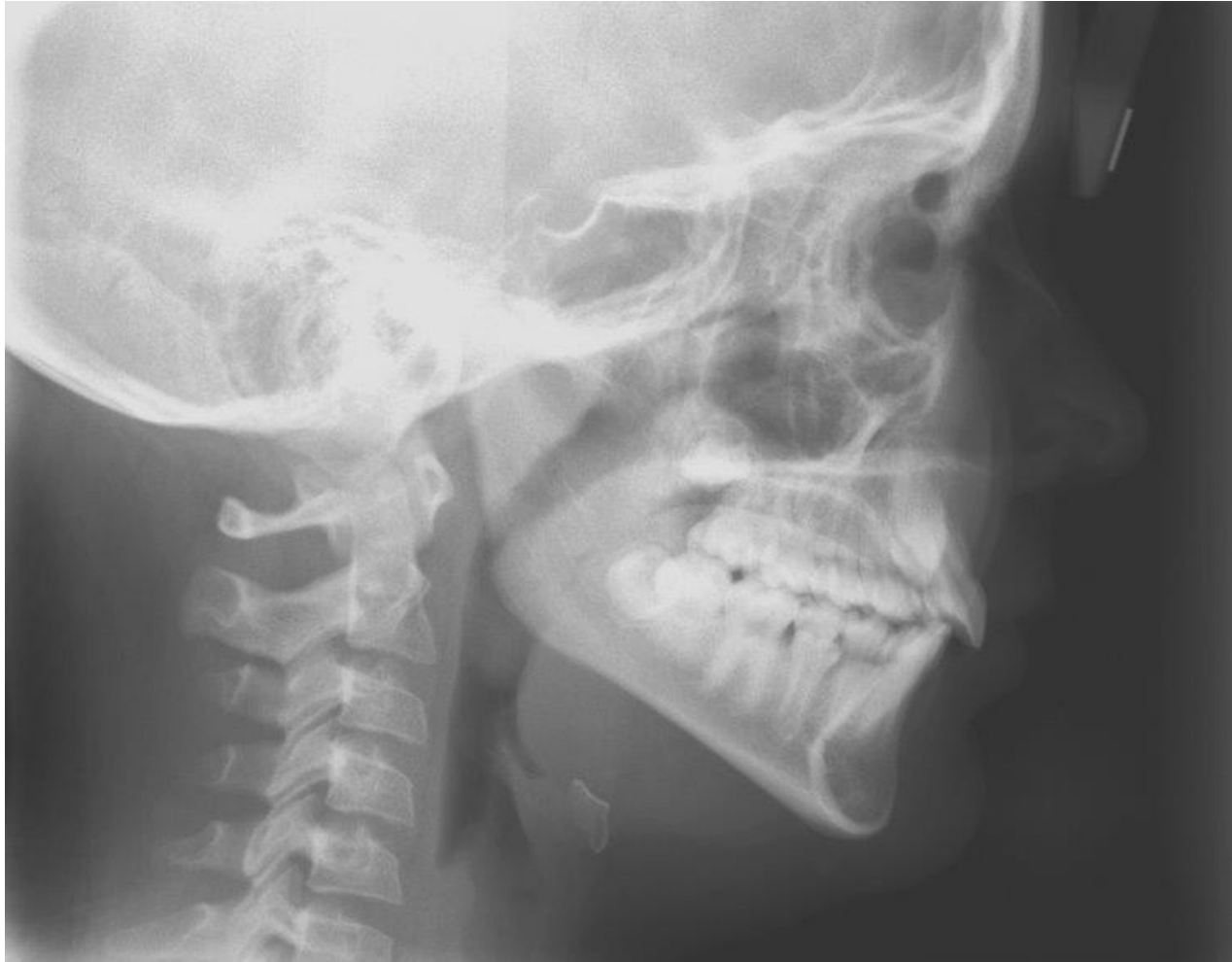Sample Case #1

Question 3



Sample Case #1

Question 3



Sample Case #1

Question 3

Classification

Domain 2: Treatment Objectives and Planning

Prompt

Provided that the crowding in the maxillary arch will be corrected with maxillary expansion and extraction of first premolars, describe how the mandibular crowding could be resolved without compromising the facial profile.

Sample Case #1

Question 3

A proficient response may include:

- Non extraction in the mandibular arch
- Maintaining the leeway space on mandibular left deciduous second molar
- Maximum anchorage on mandibular molars to move mandibular anterior teeth to the left and left canine and premolars distally
- Slight interproximal reduction on anterior teeth if needed

Possible acceptable response:

- Non extraction treatment with any of the following
 - IPR
 - LLHA
 - Stopped flush arch wire
- Must include preservation of leeway space (LL E)
- Must be a non-extraction treatment in the mandibular arch

Sample Case #1

Question 4

Classification

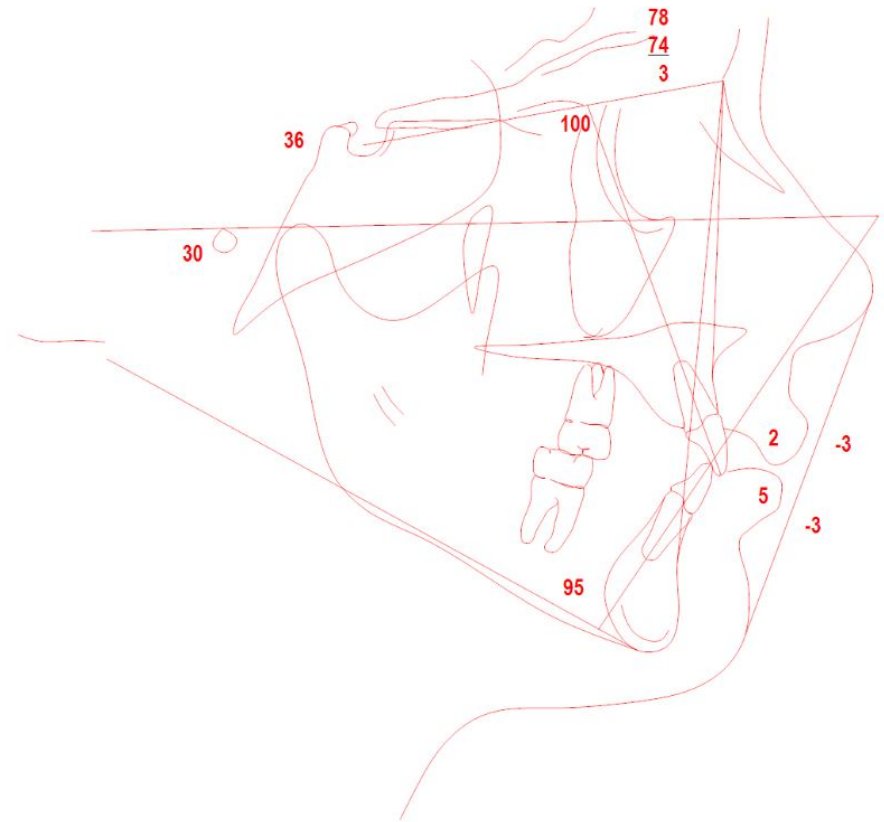
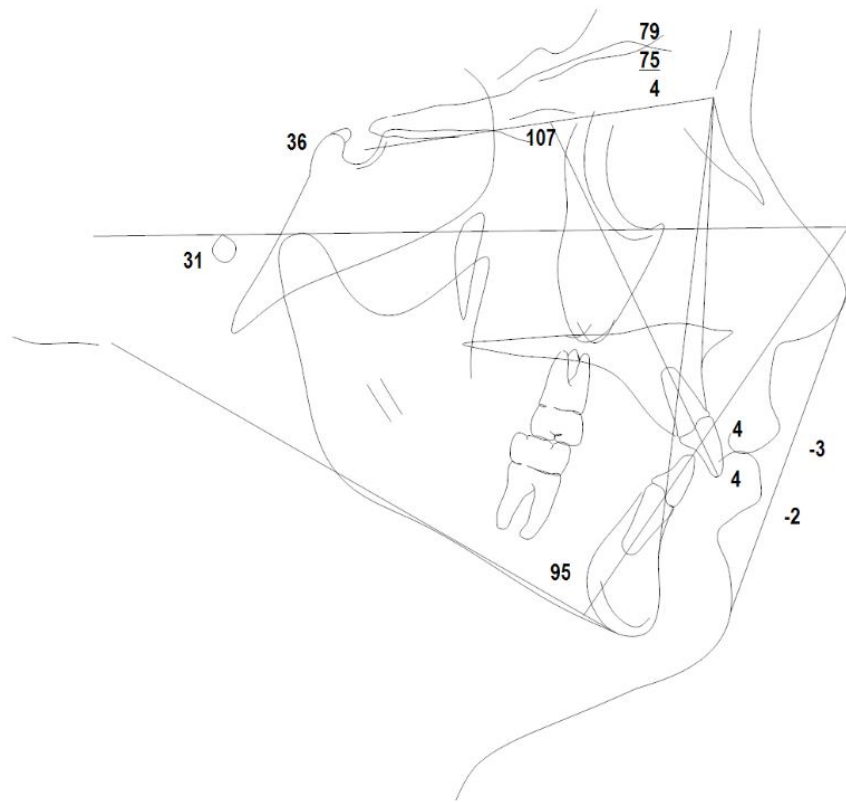
Domain 4: Critical Analysis and Outcomes Assessment

Prompt

Using the superimpositions, identify the hard tissue changes that resulted from growth and those that resulted from treatment (22 months treatment time).

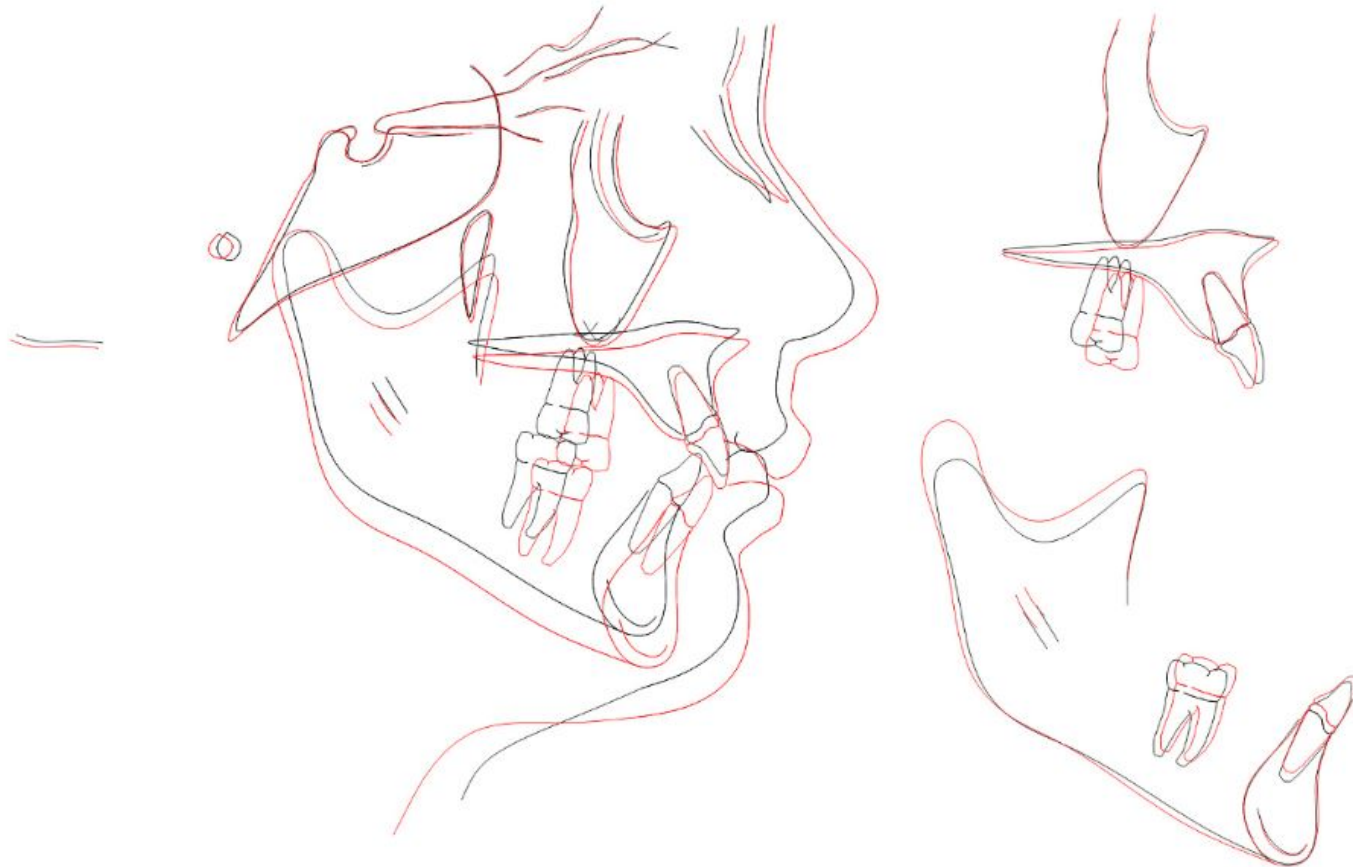
Sample Case #1

Question 4



Sample Case #1

Question 4



Sample Case #1

Question 4

A proficient response may include:

- Maxilla
 - vertical change was the result of growth
 - retracted at A point due to treatment
- Mandible
 - Pogonion (the chin) was displaced more inferior than anterior (as expected from hyperdivergent growth potential)
- Maxillary molars
 - moved mesially more than expected from growth (excess movement was due to treatment)
 - erupted with growth and extruded slightly more than would have been expected from normal growth

Sample Case #1

Question 4

Continued:

- Maxillary incisors
 - retracted due to treatment
 - held vertically due to treatment
- Mandibular molars
 - erupted with growth (there is no discernable treatment effect to the mandibular molars)
 - moved mesial slightly with growth (there is no discernable treatment effect to the mandibular molars)
- Mandibular incisors moved slightly forward as a result of growth (there is no discernable AP treatment effect on the incisors)
- Mandibular incisors moved vertical as expected from growth (there is no discernable vertical treatment effect for the mandibular incisors)

Sample Case #2



The highest commitment to excellence.

Sample Case #2

Opening Scenario:

An 8-year, 10-month-old male has been referred by a dentist for an orthodontic evaluation of permanent tooth eruption. The mother's chief complaint is that "my son grinds his teeth at night."

Sample Case #2

Question 1

Classification

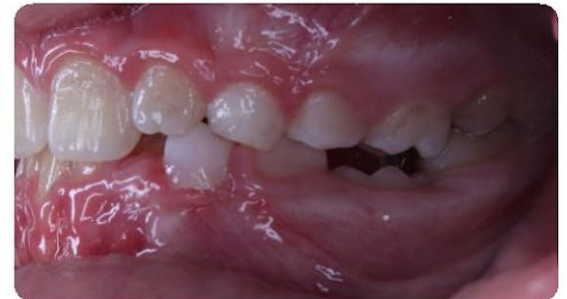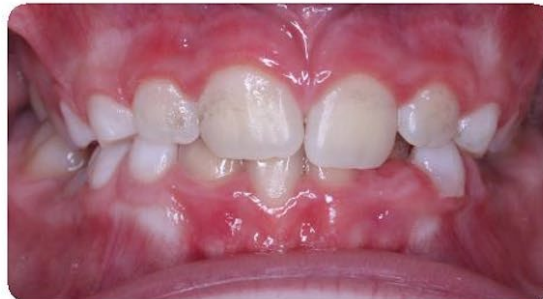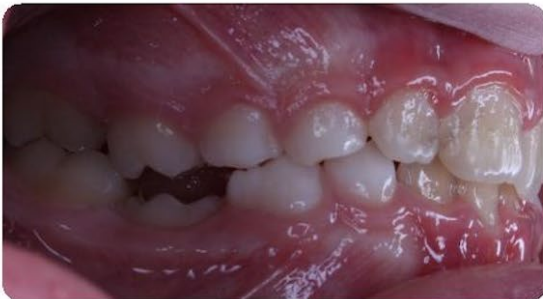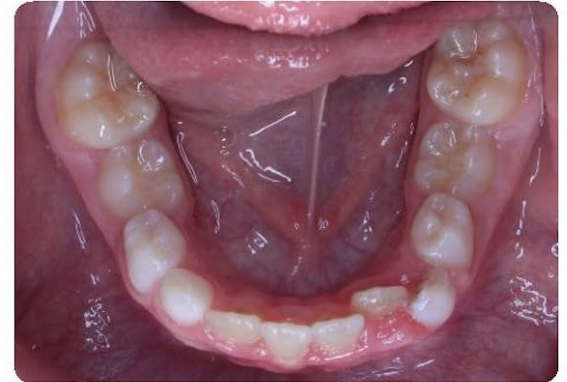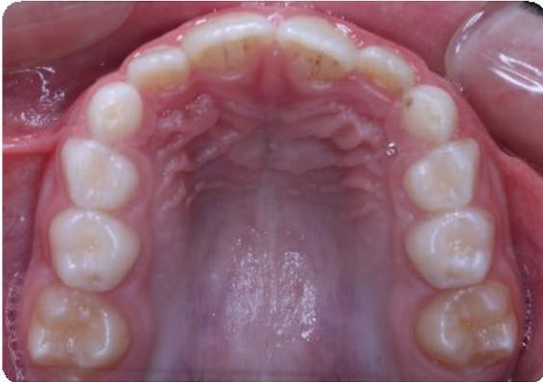Domain 1: Data Gathering and Diagnosis

Prompt

Identify all dental abnormalities evident in the intraoral photographs and the panoramic radiograph.

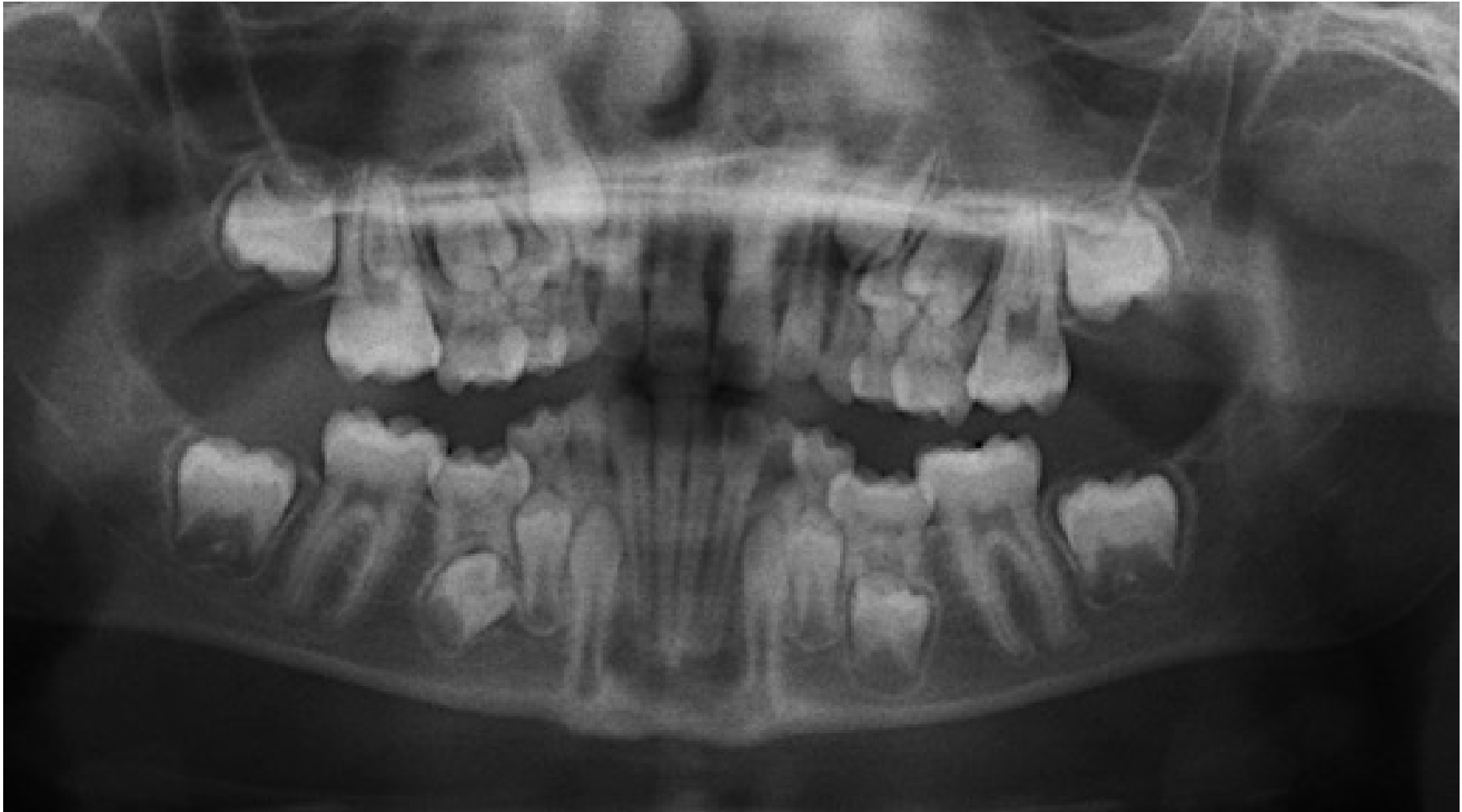Sample Case #2

Question 1



Sample Case #2

Question 1



Sample Case #2

Question 1

A proficient response may include:

- Ankylosis of the mandibular second deciduous molars
- Supra eruption of the maxillary second deciduous molars
- Mesioangulated mandibular right second premolar
- Mesial tipping of the mandibular first molars
- Mandibular anterior crowding with lingually displaced left lateral incisor
- Reduced attach gingiva on the mandibular right central incisor
- Deep overbite

Sample Case #2

Question 2

Classification

Domain 1: Data Gathering and Diagnosis

Domain 2: Treatment Objectives and Planning

Prompt

List the potential complications associated with the ankylosis of the mandibular second deciduous molars.

Sample Case #2

Question 2

A proficient response may include:

- Ectopic eruption of the mandibular second premolars
- Tipping of adjacent teeth
- Further submergence of the ankylosed mandibular second deciduous molars
- Periodontal bony defect on the ankylosed teeth
- Impaction of mandibular second premolars
- Decreased arch length
- A lateral open bite
- Extruded antagonist maxillary tooth

Sample Case #3



The highest commitment to excellence.

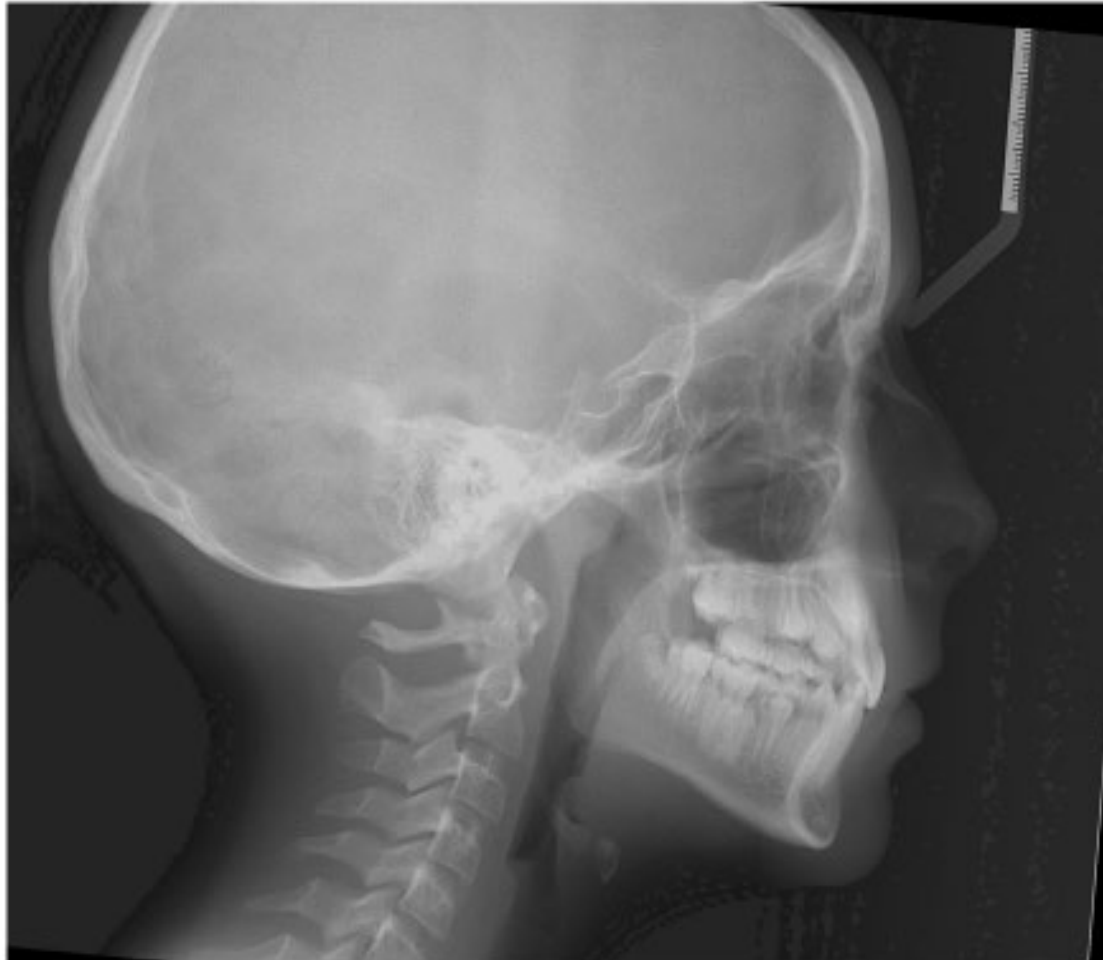Sample Case #3

Opening Scenario:

A 12-year, 5-month-old female presents without a chief complaint. Her dentist recommended an orthodontic consultation.

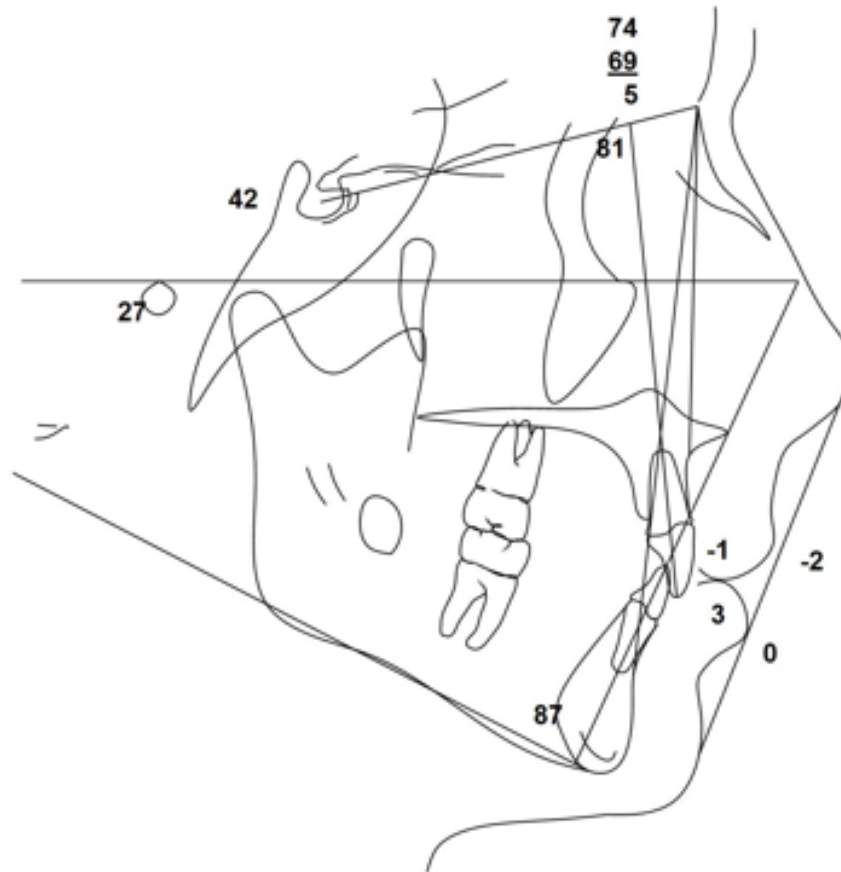
Sample Case #3

Question 1



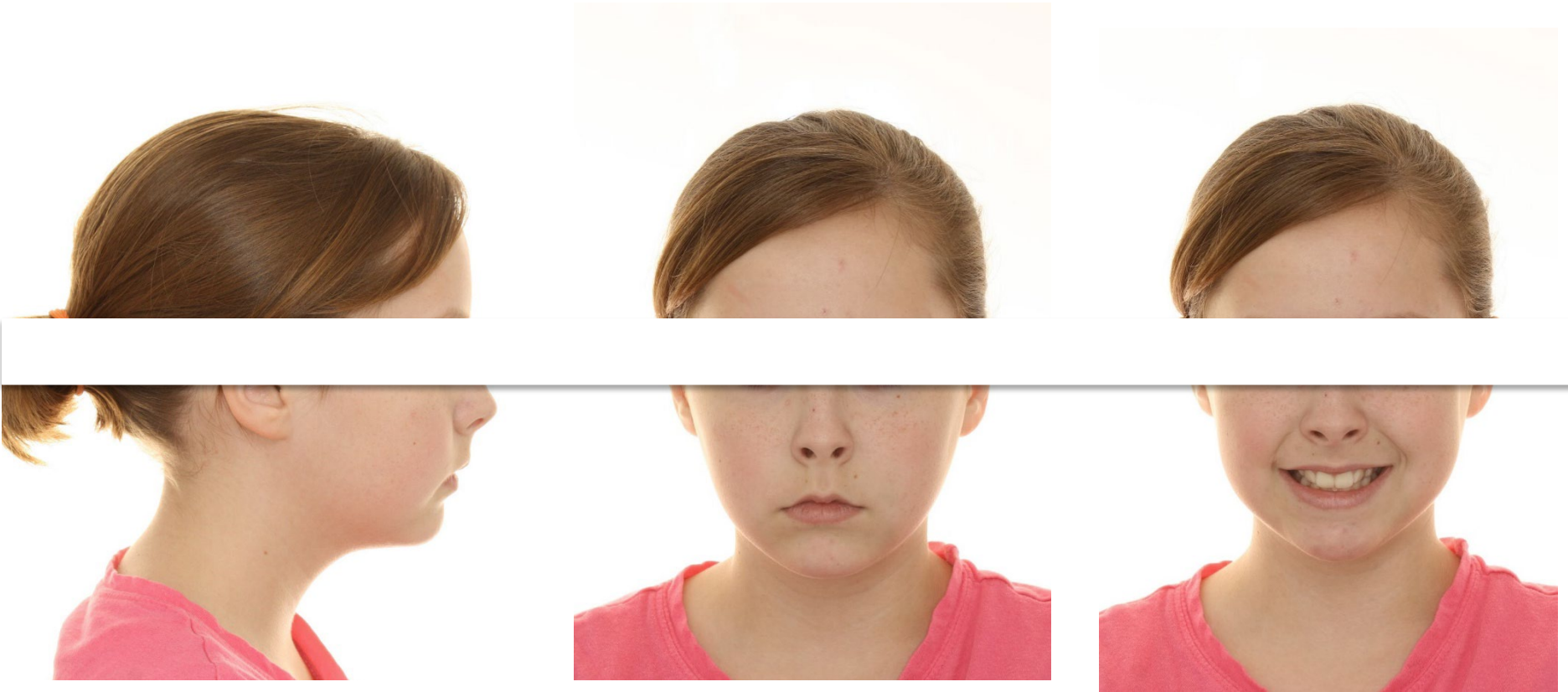Sample Case #3

Question 1



Sample Case # 3

Question 1



Sample Case #3

Question 1

Classification

Domain 1: Data Gathering and Diagnosis

Prompt

List the skeletal components of this patient's malocclusion.

Sample Case #3

Question 1

A proficient response may include:

- Steep sella-nasion relative to Frankfort horizontal
- Skeletal Class II
- Normal maxilla in AP
- Retrusive/retrognathic mandible
- Normodivergent (hyperdivergent tendency is also an acceptable answer)

Sample Case #3

Question 2

Classification

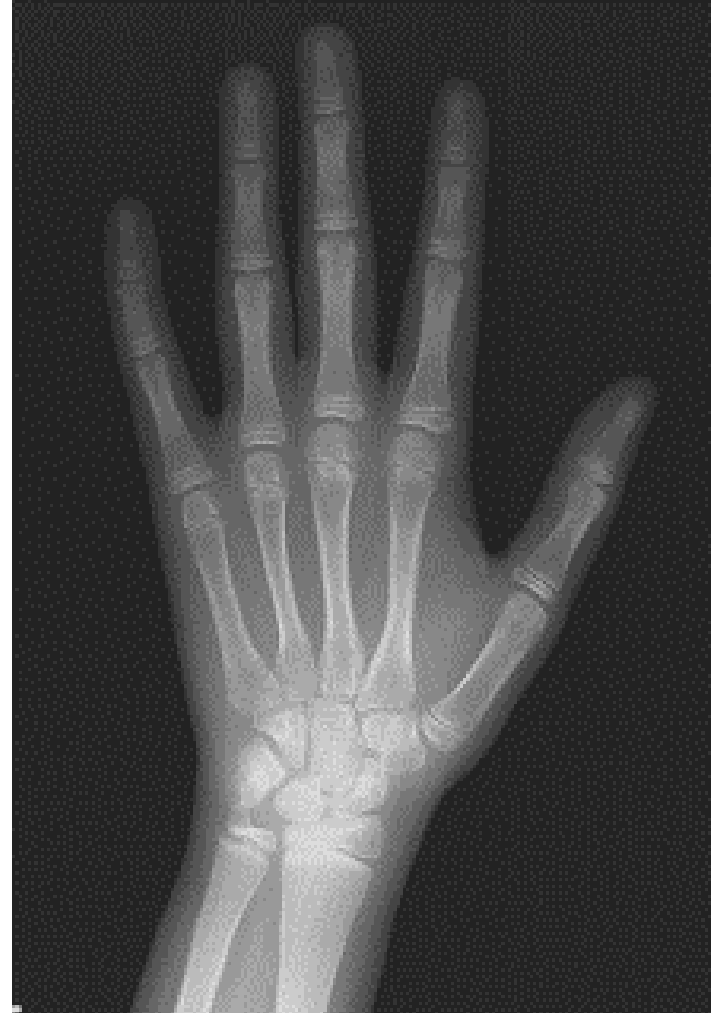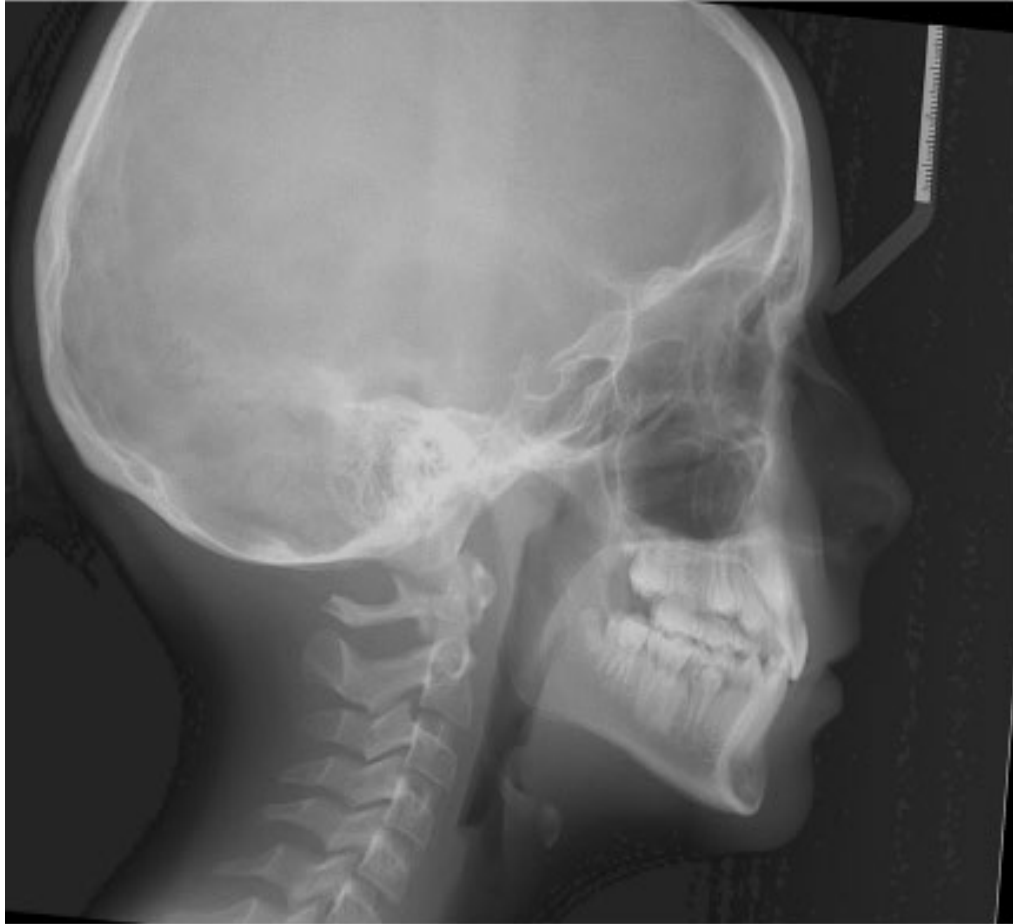Domain 2: Treatment Objectives and Planning

Prompt

Describe the patient's skeletal stage and growth potential.

Sample Case #3

Question 2



Sample Case #3

Question 2

A proficient response may include:

- Patient is expected to continue to grow (1-1.5 years) based on:
 - Cervical Vertebral Maturation Stage (CVMS) is 2 (accept between 2 and 3)
 - Skeletal Maturation Indicator (SMI) is 3 to 4

Sample Case #3

Question 3

Classification

Domain 4: Critical Analysis and Outcomes Assessment

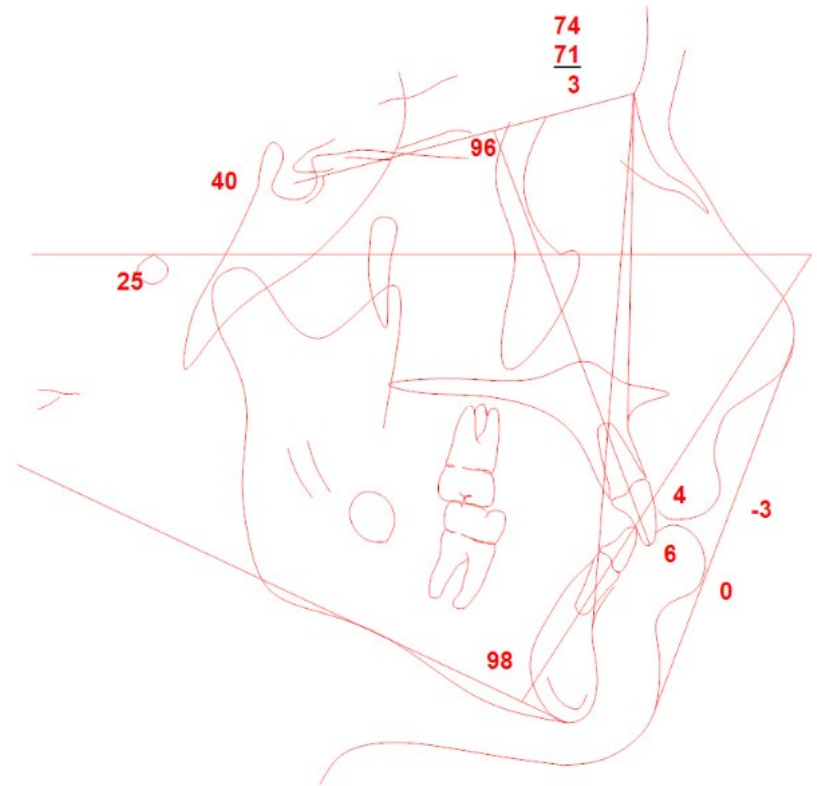
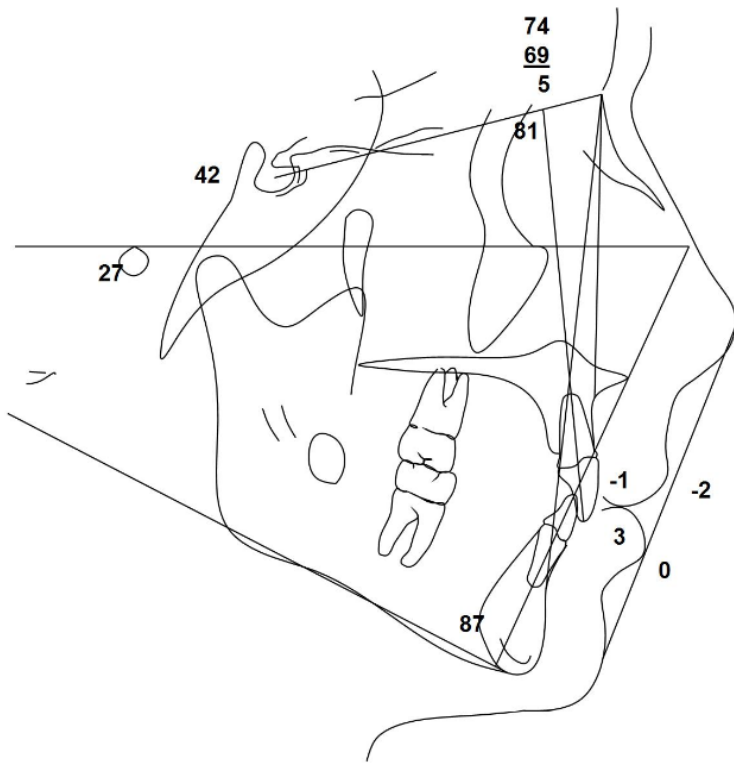
Prompt

This patient was treated with comprehensive, non extraction orthodontic treatment. The time between pre- and post-treatment records was 34 months.

What dental changes occurred as the result of treatment?

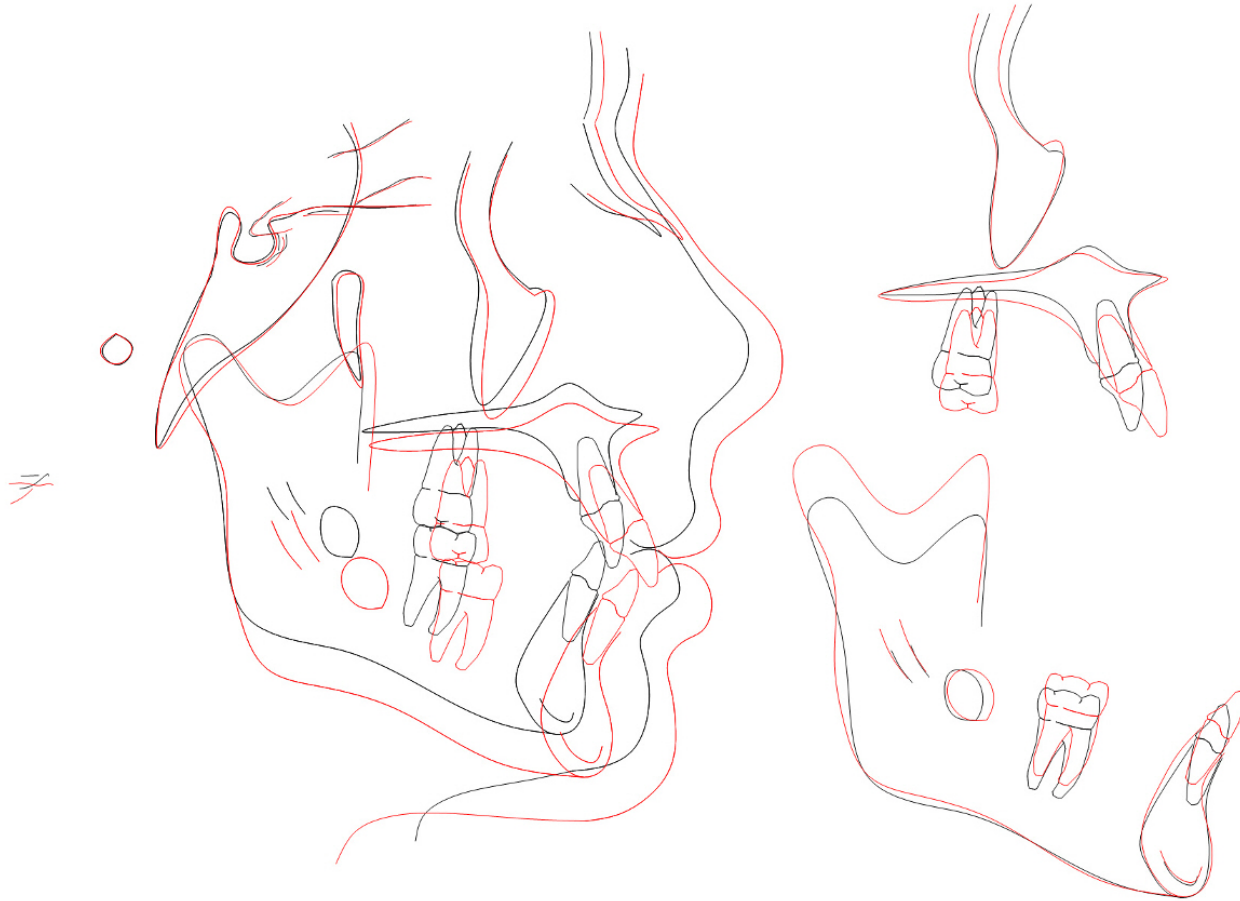
Sample Case #3

Question3



Sample Case #3

Question3



Sample Case #3

Question 3

A proficient response may include:

- Maxillary incisors were flared due to treatment
- Mandibular incisors were flared due to treatment
- *Note: All other A-P and vertical changes in tooth position were the result of normal growth*

Sample Case #4



The highest commitment to excellence.

Sample Case #4

Opening Scenario:

A 15-year, 2-month-old female presents with crowding and an open bite. The patient's chief complaint is that "my teeth are ugly."

Sample Case #4

Question 1

Classification

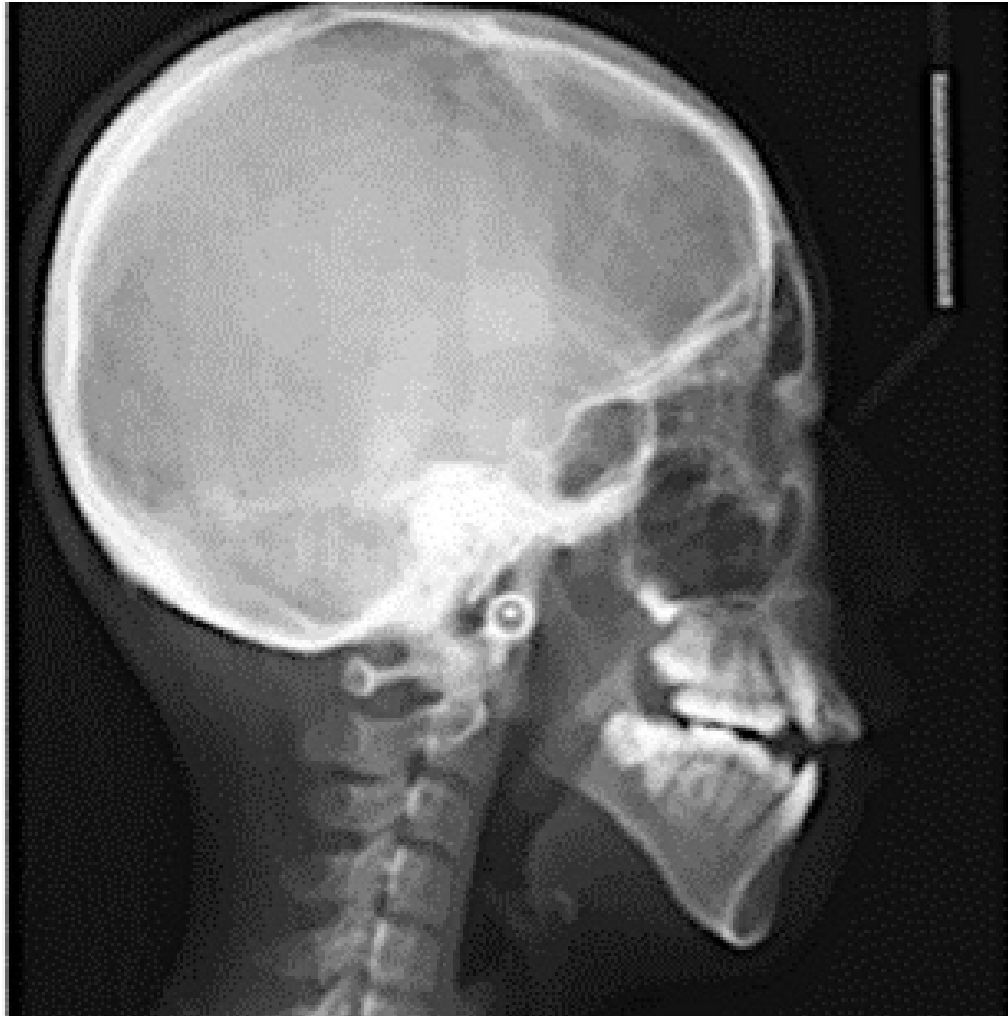- Domain 1: Data Gathering and Diagnosis

Prompt

- List the skeletal components of this patient's open bite.

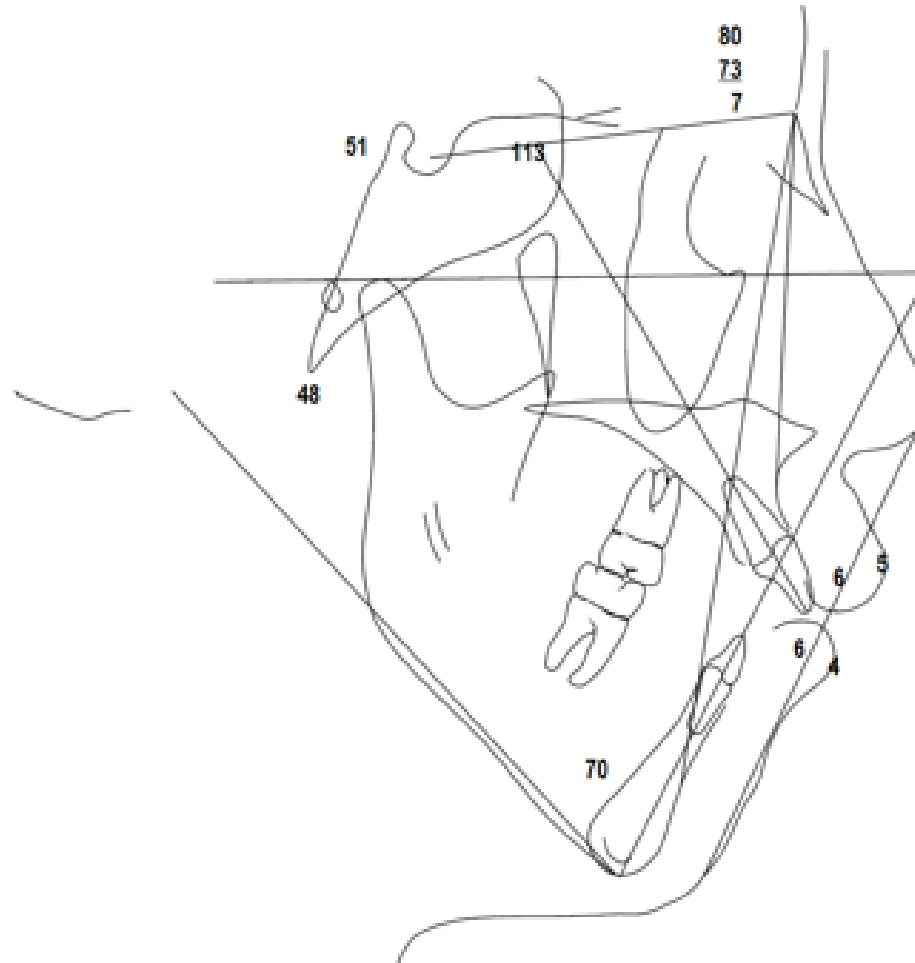
Sample Case #4

Question 1



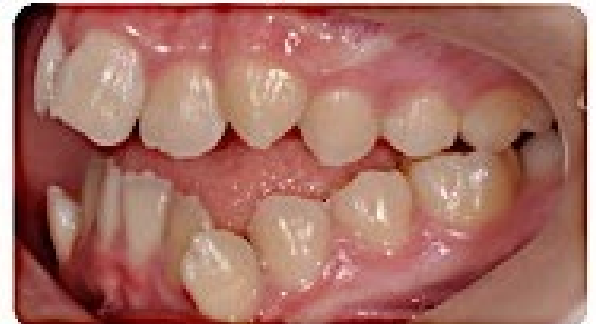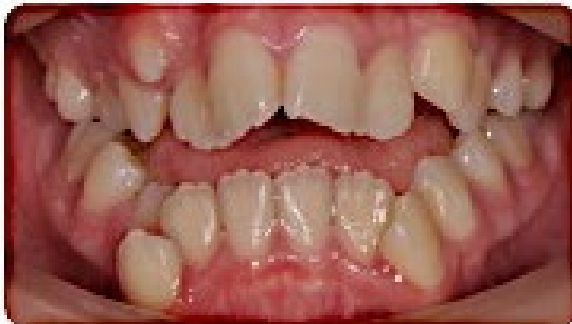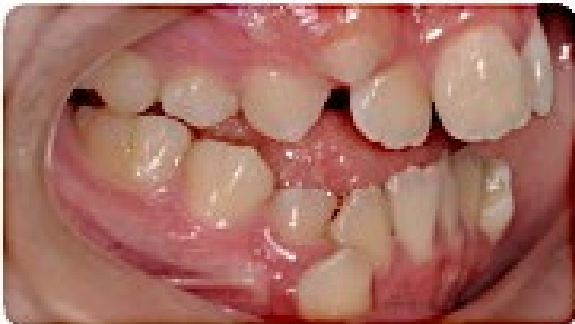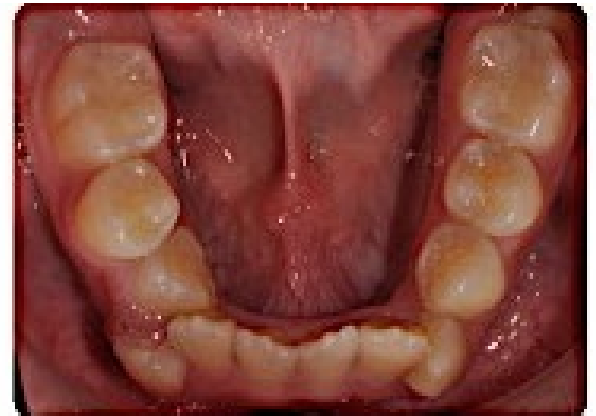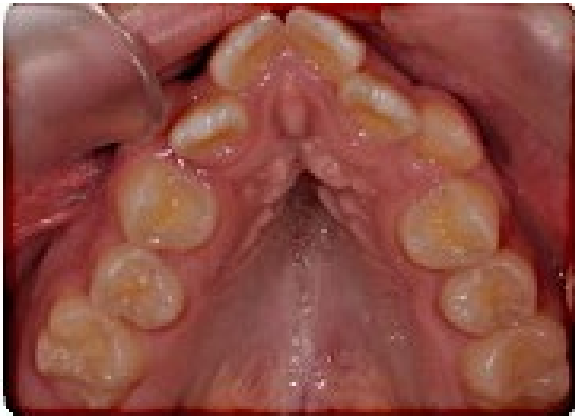Sample Case #4

Question 1



Sample Case #4

Question 1



Sample Case #4

Question 1

A proficient response may include:

- Steep mandibular plane
- Increased gonial angle
- Increased lower anterior facial height
- Short ramus height
- Decreased posterior facial height to anterior facial height ratio
- Decreased palatal plane to SN angle
- Constricted maxilla

Sample Case #4

Question 2

Classification

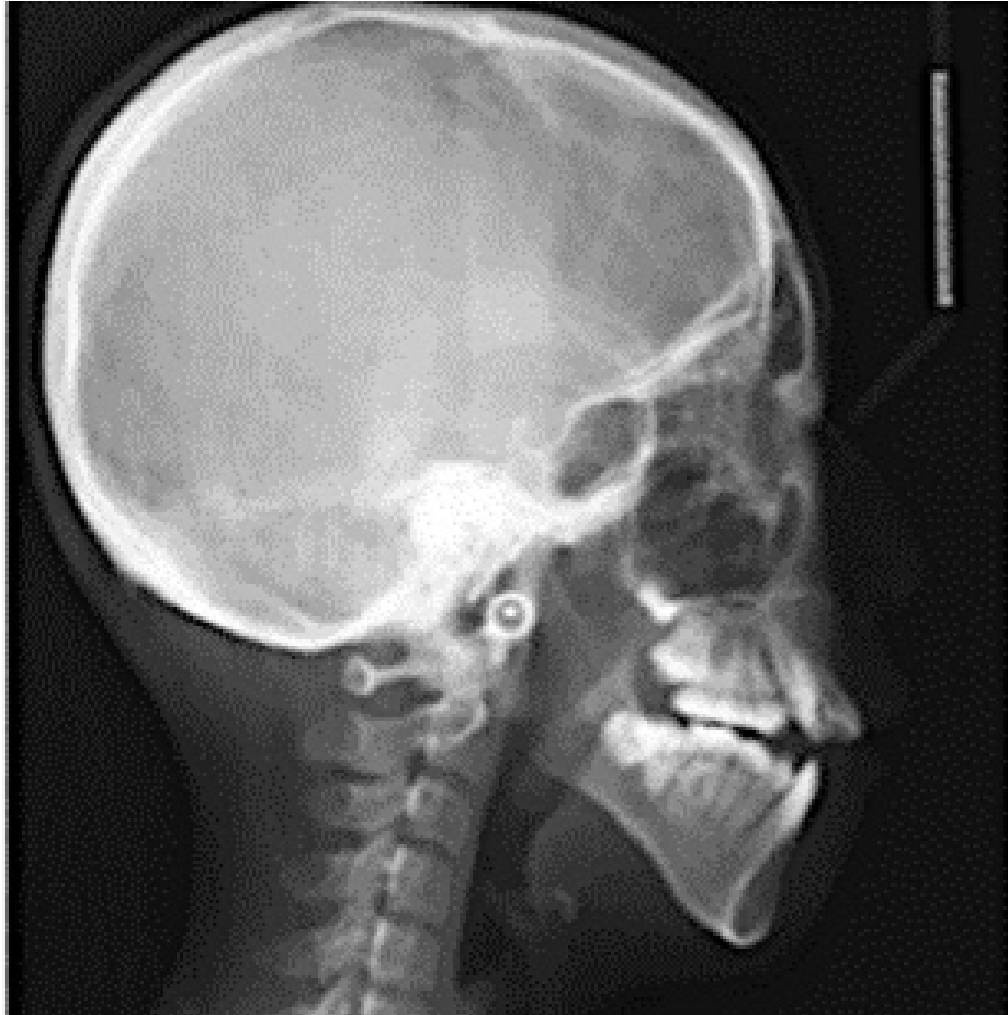- Domain 1: Data Gathering and Diagnosis

Prompt

- List the dental components of this patient's open bite.

Sample Case #4

Question 2



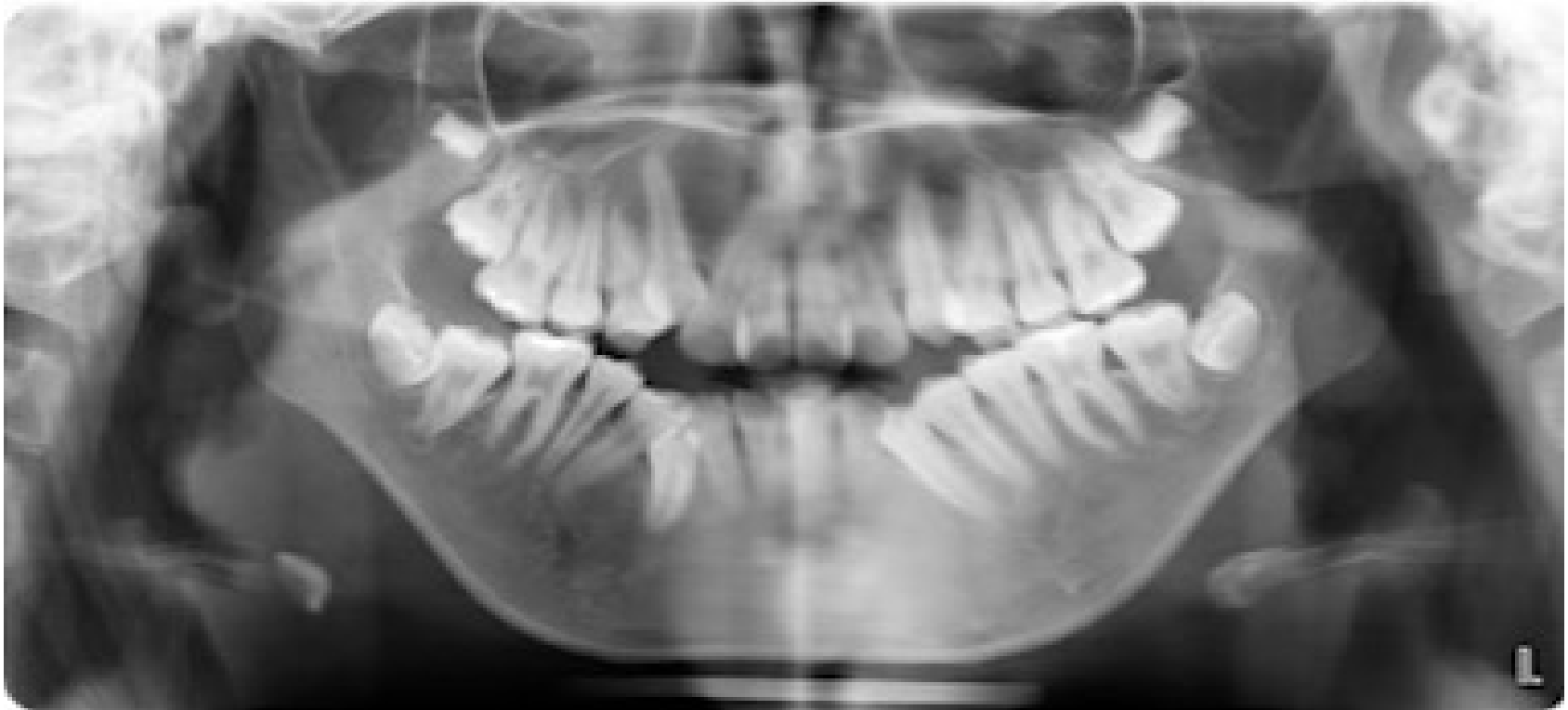Sample Case #4

Question 2



Sample Case #4

Question 2



Sample Case #4

Question 2

A possible proficient response may include:

- Constricted maxillary arch
- Overeruption of maxillary molars
- Proclination of maxillary incisors
- Infra-erupted maxillary incisors
- Overeruption of mandibular molars
- Reverse curve of Spee in the mandibular arch

Sample Case #4

Question 3

Classification

- Domain 1: Data Gathering and Diagnosis

Prompt

- Based on the intraoral photographs and cephalogram, what are the possible etiologies for this malocclusion?

Sample Case #4

Question 3

A proficient response may include:

- Genetic component (Epigenetic)
- Abnormal tongue posture
- Abnormal tongue function
- Inadequate airway/obligatory mouth breather
- Myopathy or muscle weakness

Sample Case #4

Question 4

Classification

- Domain 1: Data Gathering and Diagnosis

Prompt

- Based on the images you have seen so far, what other diagnostic tests or assessments would you undertake or request prior to initiating treatment on this patient?

Sample Case #4

Question 4

A proficient response may include:

- CBCT
- Airway assessment (polysomnography)
- Evaluation of tongue posture (Myofunctional evaluation)
- Evaluation of tongue function (Myofunctional evaluation)
- Electromyographic evaluation
- Serial cephalograms to determine whether progressive or static problem
- TEC99 scan

Sample Case #4

Question 5

Classification

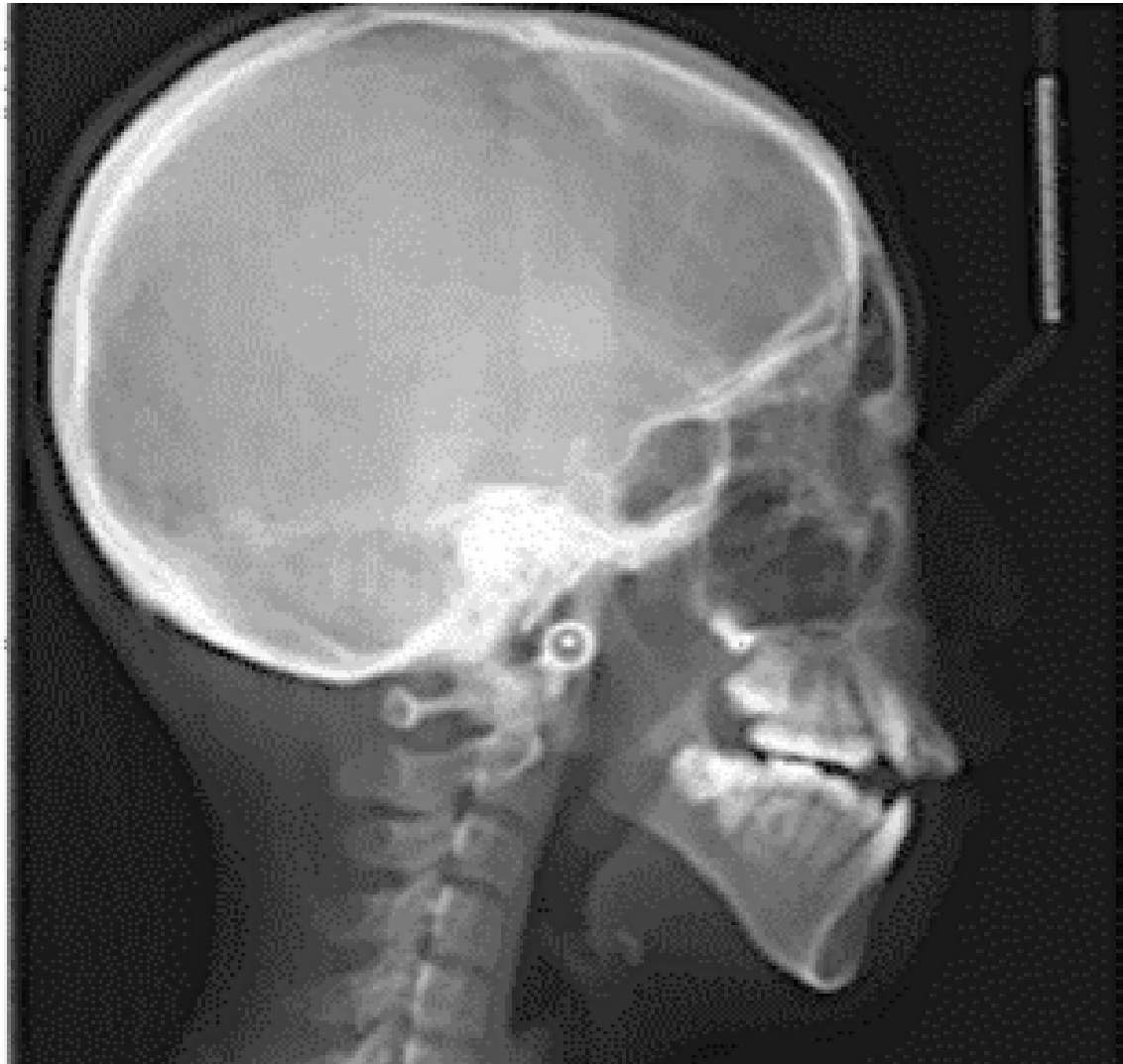- Domain 2: Treatment Objectives and Planning

Prompt

- Assuming surgical correction, describe the ideal skeletal treatment objectives for this patient.

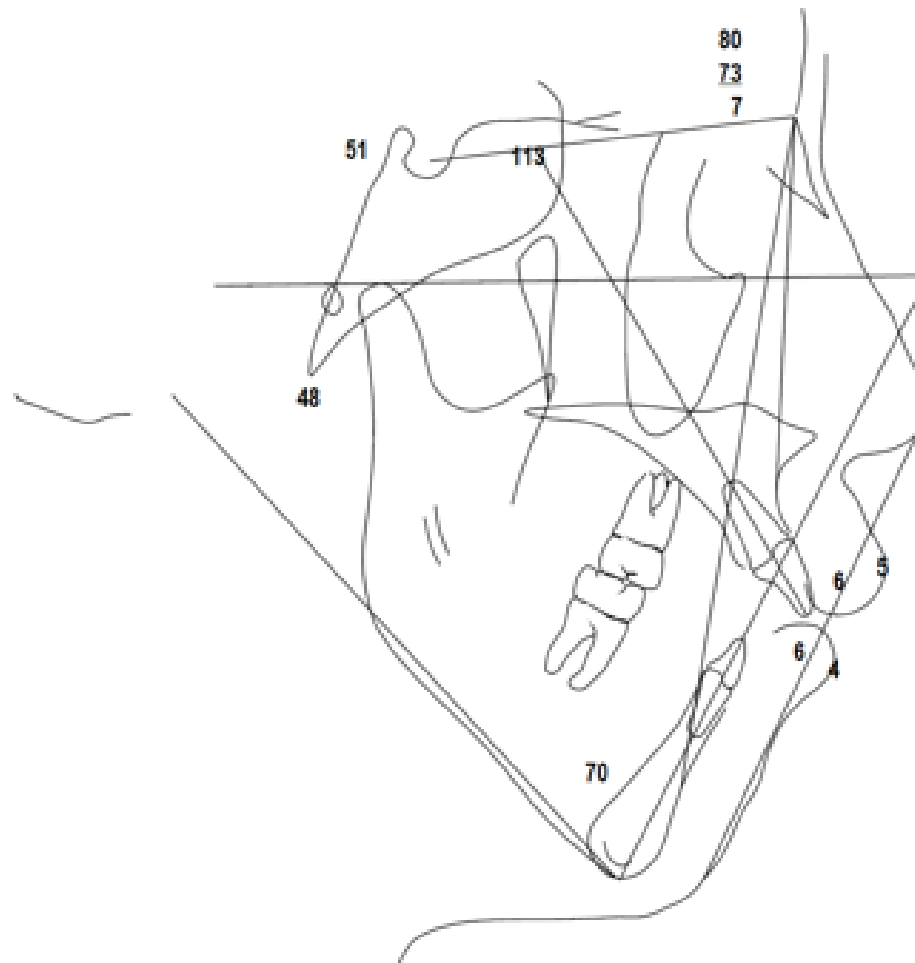
Sample Case #4

Question 5



Sample Case #4

Question 5



Sample Case #4

Question 5

A proficient response may include:

- Maxillary advancement
- Maxillary expansion
- Posterior maxillary impaction
- Reduction of lower anterior facial height
- Reduction of SN mandibular plane angle
- Superior repositioning of the mandibular distal segment (counter clockwise mandibular rotation)
- Advance the mandible (improvement of chin projection)

Sample Case #4

Question 6

Classification

- Domain 2: Treatment Objectives and Planning

Prompt

- Describe the ideal treatment plan for this patient.

****Refer to images in question # 5***

Sample Case #4

Question 6

A proficient response may include:

- Maxillary orthopedic expansion, or surgically assisted expansion, or segmental Le Fort I surgery
- Extraction of maxillary first premolars or second premolars
- Extraction of mandibular first premolars
- Extraction of all third molars
- Maxillary LeFort I surgery with posterior impaction
- Mandibular forward rotation and bilateral sagittal split ramus osteotomy
- Vertical reduction/AP augmentation genioplasty

Sample Case #4

Question 7

Classification

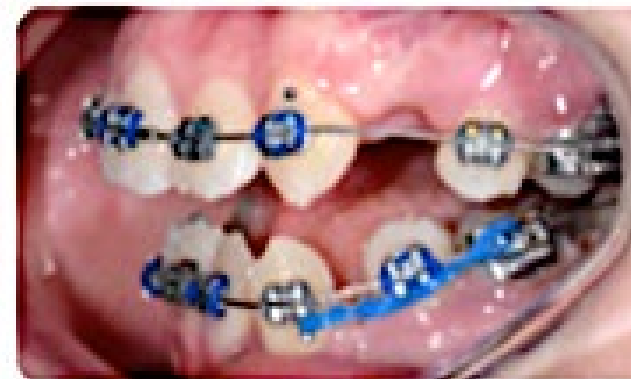
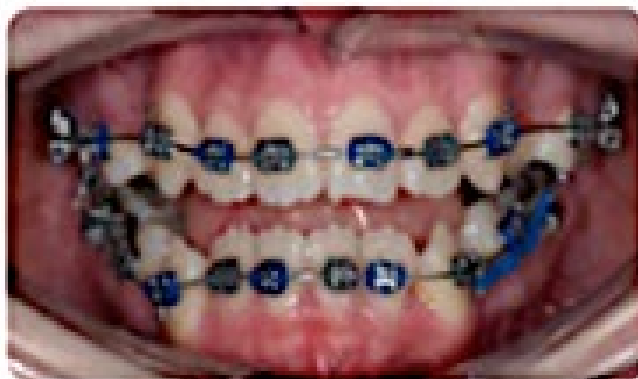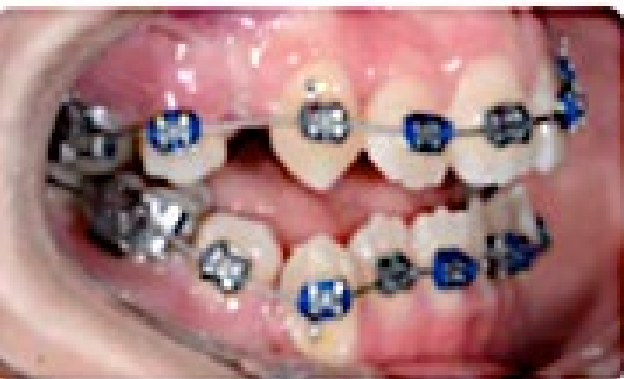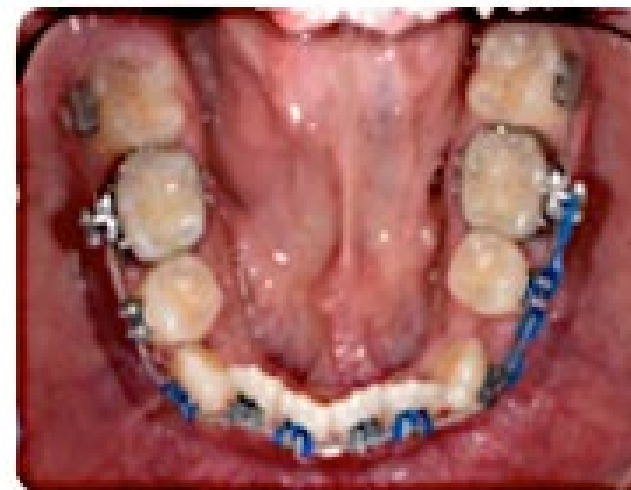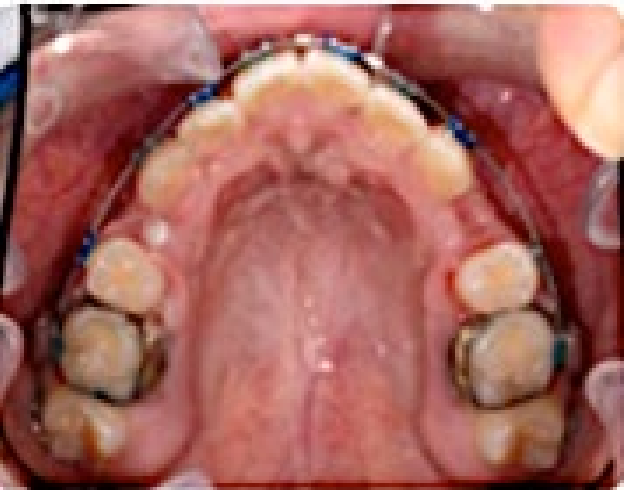- Domain 3: Treatment Implementation and Management

Prompt

- The patient has declined orthognathic surgery after treatment has been implemented. What are the next steps to attempt to correct the patient's open bite?

Sample Case #4

Question 7



Sample Case #4

Question 7

A proficient response may include:

- Trans-palatal arch
- Mandibular lingual arch
- Intrusion of mandibular molars using TADs
- Intrusion of maxillary molars using TADs or zygomatic plates
- Recommend a genioplasty post treatment